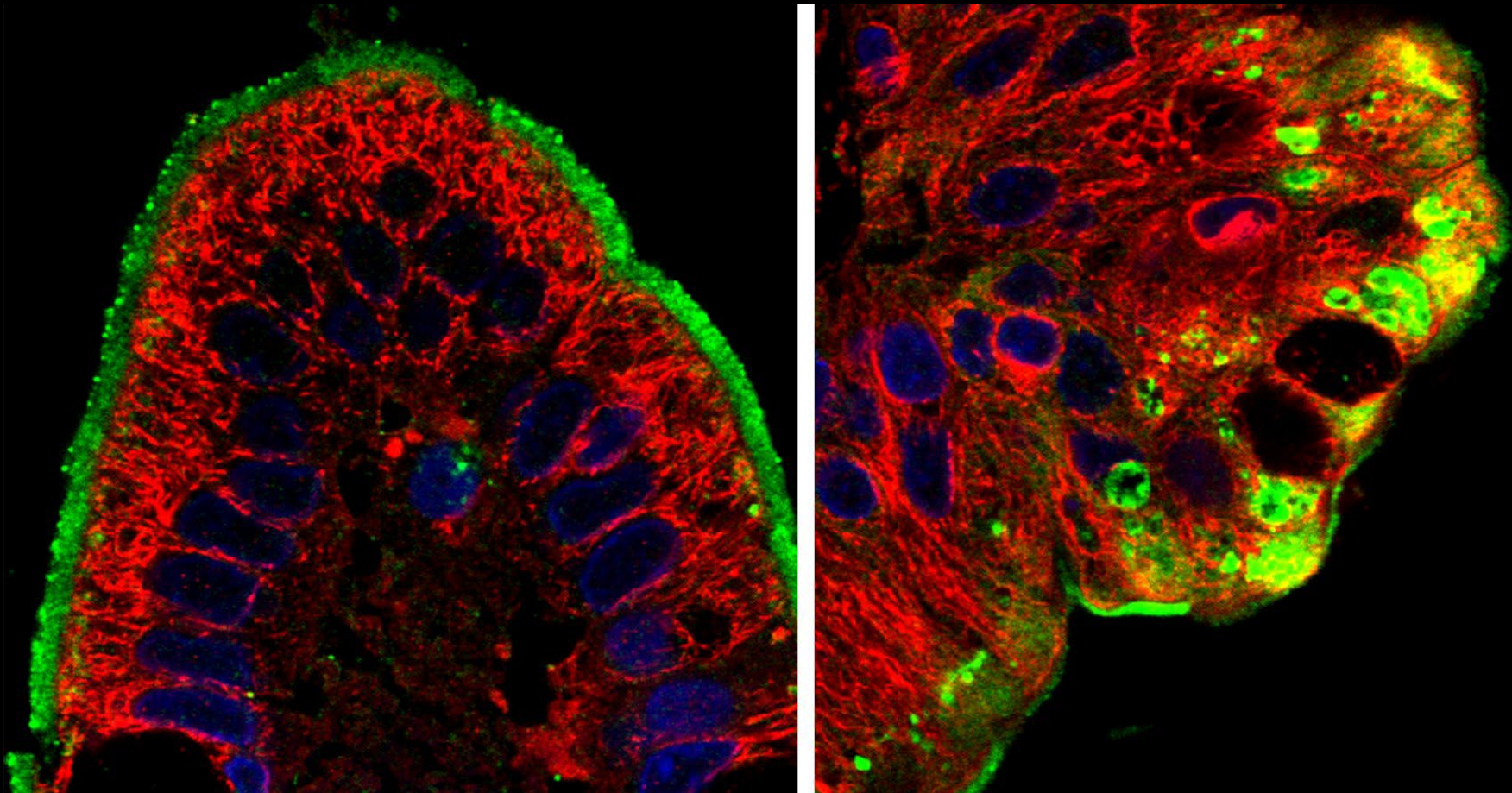


2013 ABSTRACT BOOK COVER ART COMPETITION



2013 Winner: Byron Knowles (Goldenring Lab)

On the left is a villus from a normal duodenum and on the right is a Microvillus inclusion disease villus tip. They are both stained with DPPIV-green, alpha-tubulin-red, and DAPI-blue. In the MVID patient sample you can see the formation of microvillus inclusions that are pathognomonic for this disease which are DPPIV and microtubule positive.